

Endovascular Perforator Ablation

Treatment of incompetent perforator reflux can play an important role in the management of chronic venous insufficiency and stasis ulceration.

BY CARL M. BLACK, MD; ROBERT P. SMILANICH, MD; AND EUGENE R. WORTH, MD

It has been estimated that in the US, up to approximately 2.5 million patients per year experience venous stasis ulceration.¹ Stasis ulceration results in significant morbidity and substantial economic loss. Furthermore, it is estimated that with nonoperative treatment there is an ulceration recurrence rate of between 37% and 48% at 3 and 5 years.^{2,3} Incompetent perforator reflux has been reported to contribute to chronic venous insufficiency.⁴ In addition, there is strong evidence that interruption of incompetent perforators minimizes the long-term sequelae of chronic venous insufficiency and reduces the recurrence rate of venous stasis ulceration.^{5,6}

PATHOPHYSIOLOGY OF STASIS ULCERATION

It is estimated that up to 66% of patients with skin changes secondary to chronic venous insufficiency will have a component of perforator reflux in addition to other sources of superficial or deep venous reflux.⁷ Valvular incompetency has been shown to result in venous hypertension and eventual stasis ulceration.⁸ Venous hypertension adversely affects the microcirculation by increasing vascular permeability and leakage of plasma and erythrocytes into the surrounding tissue. Research has also shown increased levels of leukocytes in dependent limbs that have been subjected to chronically elevated venous pressures. It is theorized that activated leukocytes release free radicals that contribute to tissue necrosis.⁹ Other potential mechanisms contributing to tissue necrosis include a local deficiency in fibrinolytic that results in a pericapillary fibrin cuff. It is theorized that these cuffs result in tissue hypoxia and cellular death.¹⁰

PERFORATOR ANATOMY AND DIAGNOSTIC EVALUATION

Perforating veins connect the superficial and deep systems. Larger perforators contain valves that direct flow from the superficial veins to the deep veins and are typically accompanied by a paired artery. Lower-extremity per-

forators are generally classified into one of four groups, depending on location. Hunterian perforators are found at the level of the thigh; Dodd and Boyd perforators are located just above and below the knee, respectively; and Cockett perforators are located in the calf.

Duplex ultrasound (US) evaluation is essential in the diagnostic work-up of patients suffering from venous insufficiency.¹¹ Multiple studies have demonstrated the overall effectiveness of duplex US in the evaluation of venous reflux.^{12,13} A comprehensive duplex study helps ensure complete treatment and provides a reliable tool for long-term follow-up care. Unlike evaluation for deep venous thrombosis, duplex US evaluation of the superficial system is performed with the patient in a standing position. The patient should shift his or her weight to the limb contralateral to the limb being evaluated. This position ensures maximal venous distension.¹¹ Reflux has been demonstrated in more than 90% of perforating veins with diameters >3.5mm.¹⁴ Perforator configuration is highly variable, as demonstrated in Figure 1. A tortuous perforator may be difficult to access in cases where endovenous ablation is indicated. Appropriate evaluation of the arterial system with noninvasive duplex studies is also indicated as part of a comprehensive vascular evaluation.

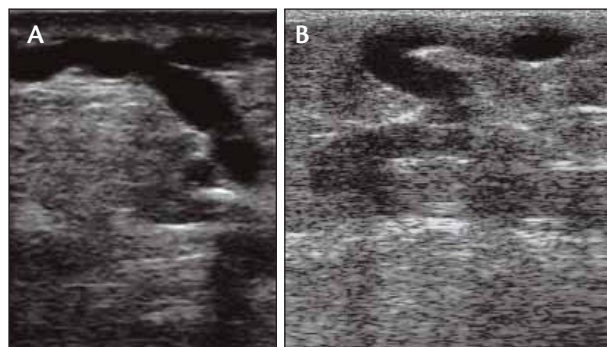


Figure 1. Examples of relatively straight (A) and tortuous (B) Cockett perforators.

SURGICAL TREATMENT

Although subfascial endoscopic surgery (SEPS) has been shown to facilitate ulcer healing, the procedure is limited by the inability to reliably access all incompetent perforator sources, which can lead to ulceration recurrence.¹⁵ In spite of the limitations of SEPS, there is strong evidence that surgical interruption of incompetent perforators minimizes the long-term sequelae of chronic venous insufficiency and reduces the recurrence rate of venous stasis ulceration.^{5,6} It is logical to assume that definitive sonographically guided endovenous perforator ablation should yield at least similar clinical results compared to those found with SEPS.

PATIENT SELECTION

It should be emphasized that abnormal perforator diameter or reflux are not the sole determinates of whether perforator treatment is warranted. We generally limit endovascular perforator treatment to those patients with pain localizing to a specific source of perforator reflux or patients with clinical, etiologic, anatomic, pathophysiologic (CEAP) classes of 4 through 6. In our practice, perforator reflux is generally addressed only after treating the principal, more central sources of superficial venous insufficiency. Often perforators that were initially found to be incompetent on the baseline duplex US evaluation become competent following ablation of the more central refluxing veins.

ENDOVENOUS TECHNIQUES

Techniques for percutaneous ablation of perforating veins are evolving. In our practice, we have used endovenous radiofrequency and laser techniques. Early success using endovenous radiofrequency and laser energy has been reported.¹⁶⁻¹⁹ Long-term follow-up data, however, are lacking.

Whether using the radiofrequency device or a fiber optic, the perforator should be accessed so that the length of vein to be treated is optimized. In tortuous perforators, only a short-segment treatment may be achieved. The tip of the ablation device should be at least .5 cm from the parent deep venous system. Although the subfascial segment of a perforator is treated with SEPS, subfascial ablation from a percutaneous approach may not always be possible. Direct device visualization under sonographic guidance is important but can be technically challenging depending on perforator depth. Once the RFS or laser fiber has been positioned, perivenous tumescent anesthesia is applied to minimize discomfort, protect surrounding tissue, and enhance device-wall apposition.

The radiofrequency technique (ClosureRFS, VNUS Medical Technologies, San Jose, CA) entails using a

radiofrequency stylet (RFS). Access can be gained into the perforator in question using either direct puncture with the RFS or access over a .035-inch guidewire. RFS ablation is typically performed by treating one or more focal levels within the perforator. Once endovascular position of the RFS is confirmed by ultrasound and an impedance of between 150 and 350 Ohms is achieved, ablation is performed at 850°C for a total of 4 minutes at each level of treatment. In addition to applying extrinsic compression during treatment, the RFS should be angulated against all four quadrants of the perforator wall for 1 minute in each quadrant. Optimally, at least two focal RFS treatments would be performed within a given perforator.

In our practice, we have also treated perforator incompetence with endovenous laser ablation (EVLA) using an 810-nm diode laser (Diomed, Andover, MA) in continuous 14-W mode. We have used 600- μ m or 400- μ m laser fibers with equivalent rates of ablation success. Endoluminal perforator access is typically achieved by advancing a stiffened introducer over a .018-inch guidewire. The laser fiber is then advanced coaxially through an introductory sheath and positioned at least .5 cm from the parent deep vein. After confirmation of laser position by US, perivenous tumescent anesthesia is applied, and energy is applied at 100 J/cm over the treatable length of the perforator. In an early series of 27 perforators treated using EVLA with close follow-up out to 6 months, we observed an ablation success rate of more than 90% on duplex US.¹⁹

Immediately after endovenous treatment with either the RFS or EVLA, a limited duplex US evaluation is performed to assure deep venous patency. A compression dressing is then applied. The patient is instructed to use compression continuously for the initial 48 hours after the procedure and then daily thereafter for the next 5 days. Patients are scheduled for a follow-up duplex ultrasound and brief clinical evaluation within 1 week.

Endovascular treatment of perforator incompetence can be technically challenging. Detailed documentation of perforator location at baseline is key to follow-up comparison. US guidance is also key to confirming an endoluminal position within the target vein. It is also important to note that perforators often run in parallel to an adjacent artery.

Percutaneous access can be a challenge. Unsuccessful needle punctures can lead to vasospasm and a perivenous hematoma, which may require the procedure to be rescheduled.

MEDICAL MANAGEMENT

Medical management of venous stasis ulceration is a mainstay of comprehensive therapy. Evidence-based protocols for venous ulcer management are employed to

(Continued on page 70)

(Continued from page 64)

provide patients with every opportunity to heal stasis ulcers.²⁰ In addition to treating the underlying hemodynamic pathophysiology, patients may require multilayered compression therapy, surgical debridement, cellular therapy, and antibiotic therapy.¹ Debridement of devitalized tissue, fibrin, and slough, and appropriate topical therapy should be instituted early in venous ulcer management. Compression therapy is applied in a serial fashion in order to manage chronic edema found in many of these patients. Tubigrips are applied in a double layer provide 15 to 18 mm Hg of concentric pressure. Other modalities of compression therapy to achieve progressively higher compression may be required.

Should the ulcer not respond by moving toward closure, surgical intervention with split-thickness skin graft or bioengineered skin substitute is also considered. Because many patients suffering from chronic venous insufficiency have significant and complex comorbidities, close collaboration among various specialties, such as interventionists, surgeons, plastic surgeons, and wound care specialists, optimizes patient care.

CONCLUSION

It is well established that perforator reflux contributes to chronic venous insufficiency and venous stasis ulceration. Endovenous techniques will likely supplant traditional SEPS for perforator interruption and, in properly selected cases, will play an increasingly important role in the overall management of venous insufficiency. In light of the complex nature of venous disease and wound care, a multidisciplinary approach is encouraged. ■

Carl M. Black, MD, is the cofounder of the Intermountain Vein Center and Chairman of Utah Valley Radiology Associates in Provo, Utah. He has disclosed that he holds no financial interest in any product or manufacturer mentioned herein. Dr. Black may be reached at (801) 357-8770; carl.black@comcast.net.

Robert P. Smilanich, MD, is Director of Vascular Surgery, Utah Vascular Center in Provo, Utah. He has disclosed that he holds no financial interest in any product or manufacturer mentioned herein. Dr. Smilanich may be reached at (801) 374-9100; uvc@comcast.net.

Eugene R. Worth, MD, is Director of Hyperbaric Medicine and the Wound Care Clinic, Utah Valley Regional Medical Center in Provo, Utah. He has disclosed that he holds no financial interest in any product or manufacturer mentioned herein. Dr. Worth may be reached at (801) 357-8156; eugene.worth@intermountainmail.org.

1. Valencia IC, Falabella A, Kirsner RS, et al. Chronic venous insufficiency and venous leg ulceration. *J Am Acad Dermatol.* 2001;44:401-424.
2. McDaniel HB, Marston WA, Farber MA, et al. Recurrence of chronic venous ulcers on the basis of clinical, etiologic, anatomic, and pathophysiologic criteria and air plethysmography. *J Vasc Surg.* 2002;35:723-728.
3. Erickson CA, Lanza DJ, Karp DL, et al. Healing of venous ulcers in an ambulatory care program: the roles of chronic venous insufficiency and patient compliance. *J Vasc Surg.* 1995;22:629-636.
4. Cockett F. The pathology and treatment of venous ulcers of the leg. *Br J Surg.* 1955;43:260-278.
5. Gloviczki P, Bergan JJ, Rhodes JM, et al. Mid-term results of endoscopic perforator vein interruption for chronic venous insufficiency: lessons learned from the North American subfascial endoscopic perforator surgery registry. The North American Study Group. *J Vasc Surg.* 1999;29:489-502.
6. Pierik EG, van Urk H, Wittens CH. Efficacy of subfascial endoscopy in eradicating perforating veins of the lower leg and its relation with venous ulcer healing. *J Vasc Surg.* 1997;26:255-259.
7. Myers KA, Ziegenbein RW, Zeng GH, et al. Duplex ultrasonography scanning for chronic venous disease: patterns of venous reflux. *J Vasc Surg.* 1995;21:605-612.
8. Lees TA, Lambert D. Patterns of venous reflux in limbs with skin changes associated with chronic venous insufficiency. *Br J Surg.* 1993;80:725-728.
9. Falanga V, Eaglstein WH. The "trap" hypothesis of venous ulceration. *Lancet.* 1993;341:1006-1008.
10. Wolfe JH, Morland M, Browse NL. The fibrinolytic activity of varicose veins. *Br J Surg.* 1979;66:185-187.
11. Minn RJ, Khilnani NM, Golia P. Duplex Ultrasound evaluation of lower extremity venous insufficiency. *J Vasc Interv Radiol.* 2003;14:1233-1241.
12. Neglin P, Raju S. A comparison of descending phlebography and duplex Doppler investigation in the evaluation of reflux in chronic venous insufficiency: A challenge to phlebography as the "gold standard." *J Vasc Surg.* 1992;16:687-693.
13. Welch HJ, Faliakou EC, McLaughlin RL, et al. Comparison of descending phlebography with quantitative photoplethysmography, air plethysmography, and duplex quantitative valve closure time in assessing deep venous reflux. *J Vasc Surg.* 1992;16:913-920.
14. Sandri JL, Barros FS, Pontes S, et al. Diameter-reflux relationship in perforating veins of patients with varicose veins. *J Vasc Surg.* 1999;30:867-874.
15. van Rij AM, Hill G, Gray C, et al. A prospective study of the fate of venous leg perforators after varicose vein surgery. *J Vasc Surg.* 2005;42:1156-1162.
16. Proebstle TM, Herdeman S. Feasibility of incompetent perforator vein ablation by endovenous laser treatment. Abstract presented at the 20th American College of Phlebology Congress, 2006.
17. Peden E, Lumsden A. Radiofrequency ablation of incompetent perforator veins. *Perspect Vasc Surg Endovasc Ther.* 2007;19:73-77.
18. Chang DW, Levy RM, Hayashi RW, et al. Percutaneous catheter treatment of perforating vein incompetence using ultrasound guided radiofrequency ablation. Poster presented at the 33rd annual meeting of the Society for Clinical Vascular Surgery, 2005.
19. Black CM, Hatch D, Brown D, et al. An endovenous approach to symptomatic perforator ablation. *J Vasc Interv Radiol.* 2007;18(1 Suppl 2):S23.
20. Brem H, Kirsner RS, Falanga V. Protocol for the successful treatment of venous ulcers. *Am J Surg.* 2004;188(1A Suppl):1-8.